
Recurrent interface infiltration with hypopyon after astigmatic laser in situ keratomileusis on a penetrating corneal graft

Thomas Reinhard, MD, Michael Knorz, MD, Rainer Sundmacher, MD, FRCOphth

A 56-year-old woman was referred with recurrent interface infiltration and hypopyon after astigmatic laser in situ keratomileusis (LASIK) on a corneal graft. *Pseudomonas aeruginosa* was isolated as the causative pathogen. Penetrating keratoplasty had been performed 2 years before refractive surgery. After the antibiotic medication was tapered, 3 recurrences of interface infiltration with hypopyon were observed. Penetrating rekeratoplasty was deemed appropriate. Histological examination of the explanted corneal graft revealed anterior stromal neutrophil infiltration. This case illustrates that microbial pathogens brought underneath the flap by LASIK can persist months later despite antimicrobial treatment.

J Cataract Refract Surg 2004; 30:257–258 © 2004 ASCRS and ESCRS

Microbial keratitis after laser in situ keratomileusis (LASIK) has been described several times since 1997.^{1–13} We report recurrent interface infiltration with hypopyon after astigmatic LASIK on a penetrating corneal graft.

Case Report

Penetrating keratoplasty (PKP) was performed on a 63-year-old woman in June 1995 due to Fuchs' endothelial dystrophy. Because of high post-keratoplasty astigmatism, LASIK on the graft was performed twice in July 1997. The same aseptic measures as with intraocular procedures were used (ie, disinfection of the skin with povidone–iodine 10%, disinfection of the conjunctiva with povidone–iodine 0.1%, rinsing of the conjunctiva with sterile sodium chloride 0.9%, and gluing a foil on the skin and the eyelashes). During the postoperative course, topical gentamicin was administered. One week after

the last refractive procedure, an interface infiltration was observed. Under topical therapy with gentamicin, ciprofloxacin, and amikacin, no improvement was observed in the following 4 weeks.

The flap was elevated, and material scraped from beneath it was cultured microbiologically. Rinsing with vancomycin was performed underneath the flap. *Pseudomonas aeruginosa* was found to be the causative agent. A microbiological examination showed antibiotic sensitivity to mezlocillin, piperacillin, and tacobactam but not gentamicin, ofloxacin, amikacin, ampicillin, tetracycline, cefuroxim, cefotaxime, and cefazolin. Topical therapy with mezlocillin and systemic therapy with piperacillin and tacobactam was initiated and tapered over 4 weeks. Thereafter, 2 recurrences of interface infiltration with hypopyon occurred and were successfully treated with topical and systemic antibiotics.

When the third recurrence was observed in December 1997 (Figure 1), another PKP was performed. No further infections were observed. The graft has remained clear for 4.5 years (Figure 2). Current endothelial cell density in the graft center is 422 cells/mm.² Histopathological examination showed anterior stromal neutrophil infiltration of the first graft.

Discussion

Interface keratitis with hypopyon is a rare complication of LASIK.^{1–13} Various bacterial and fungal strains have been identified as causative pathogens.^{1–13} In this patient, recurrent interface keratitis with hypopyon

Accepted for publication May 29, 2003.

From the Eye Hospital, Albert-Ludwig's University (Reinhard), Freiburg, the Eye Hospital, Heinrich-Heine University (Reinhard, Sundmacher), Düsseldorf, and the Eye Hospital, University of Mannheim (Knorz), Mannheim, Germany.

None of the authors has a financial or proprietary interest in any material or method mentioned.

Reprint requests to Thomas Reinhard, MD, Killianstrasse 5, 79106, Freiburg, Germany. E-mail: reinhard@aug.uki.uni-freiburg.de.

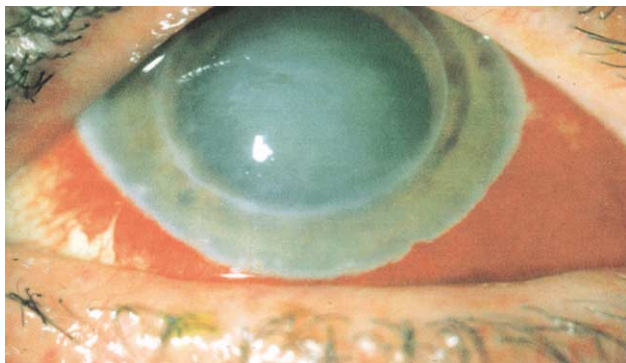

Figure 1. (Reinhard) Interstitial keratitis on the graft of a patient after astigmatic LASIK.

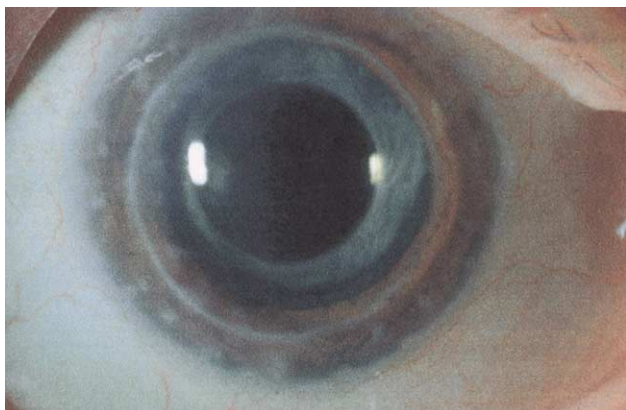


Figure 2. (Reinhard) The eye 4.5 years after penetrating keratoplasty. Cataract surgery and implantation of an intraocular lens in the capsular bag were performed within this time.

developed after astigmatic LASIK on a corneal graft. Gentamicin (effective in 91% of *Staphylococcus aureus*, 77% of *P aeruginosa*, and 52% of *Staphylococcus epidermidis* cases¹⁴), ciprofloxacin (effective in almost 100% of cases for the eradication of gram-negative organisms that cause conjunctivitis¹⁴), and amikacin (effective in 96% of *P aeruginosa* cases¹⁴) were administered before the flap was rinsed underneath. Topical administration of these drugs, however, did not eradicate the unknown pathogen. Therefore, vancomycin (effective in nearly 100% of staphylococci and streptococci cases¹⁴) was used for rinsing underneath the flap. Thereafter, mezlocillin, piperacillin, and tacobactam were administered. Although the latter antibiotics have been effective in treating the causative agent, further episodes occurred. Penetration of the drugs was probably too modest for eradication of *P aeruginosa* underneath the flap.

Although preoperative, intraoperative, and postoperative aseptic and prophylactic measures were used,

interstitial keratitis could not be avoided. This case illustrates that we must further improve our prophylactic measures and shows that microbial pathogens brought underneath the flap by LASIK can persist months later, despite antimicrobial treatment. This case also demonstrates that a repeat PKP may be necessary for patient rehabilitation.

References

1. Pérez-Santonja JJ, Sakla HF, Abad JL, et al. Nocardial keratitis after laser in situ keratomileusis. *J Refract Surg* 1997; 13:314–317
2. Mulhern MG, Condon PI, O'Keefe M. Endophthalmitis after astigmatic myopic laser in situ keratomileusis. *J Cataract Refract Surg* 1997; 23:948–950
3. Aras C, Özdamar A, Bahçecioglu H, Sener B. Corneal interface abscess after excimer laser in situ keratomileusis. *J Refract Surg* 1998; 14:156–157
4. Reviglio V, Rodriguez ML, Picotti GS, et al. Mycobacterium chelonae keratitis following laser in situ keratomileusis. *J Refract Surg* 1998; 14:357–360
5. Kim H-M, Song J-S, Han H-S, Jung H-R. Streptococcal keratitis after myopic laser in situ keratomileusis. *Korean J Ophthalmol* 1998; 12:108–111
6. Al-Reefy M. Bacterial keratitis following laser in situ keratomileusis for hyperopia. *J Refract Surg* 1999; 15: S216–S217
7. Webber SK, Lawless MA, Sutton GL, Rogers CM. Staphylococcal infection under a LASIK flap. *Cornea* 1999; 18:361–365
8. Lam DSC, Leung ATS, Wu JT, et al. Culture-negative ulcerative keratitis after laser in situ keratomileusis. *J Cataract Refract Surg* 1999; 25:1004–1008
9. Sridhar MS, Garg P, Bansal AK, Sharma S. Fungal keratitis after laser in situ keratomileusis. *J Cataract Refract Surg* 2000; 26:613–615
10. Garg P, Bansal AK, Sharma S, Vemuganti GK. Bilateral infectious keratitis after laser in situ keratomileusis; a case report and review of the literature. *Ophthalmology* 2001; 108:121–125
11. Levartovsky S, Rosenwasser GOD, Goodman DF. Bacterial keratitis after laser in situ keratomileusis. *Ophthalmology* 2001; 108:321–325; errata, 1012
12. Kouyoumdjian GA, Forstot SL, Durairaj VD, Damiano RE. Infectious keratitis after laser refractive surgery. *Ophthalmology* 2001; 108:1266–1268
13. Gupta V, Dada T, Vajpayee RB, et al. Polymicrobial keratitis after laser in situ keratomileusis. *J Refract Surg* 2001; 17:147–148
14. Mauger TF. Antimicrobials. In: Mauger TF, Craig EL, eds. *Havener's Ocular Pharmacology*, 6th ed. St Louis, MO, Mosby, 1994; 234–349