

Femtosecond Laser Capsulotomy and Manual Continuous Curvilinear Capsulorrhexis Parameters and Their Effects on Intraocular Lens Centration

Kinga Kránitz, MD; Agnes Takacs, MD; Kata Miháltz, MD; Illés Kovács, MD, PhD; Michael C. Knorz, MD; Zoltán Z. Nagy, MD, DSC

ABSTRACT

PURPOSE: To measure and compare sizing and positioning parameters of femtosecond laser capsulotomy with manual continuous curvilinear capsulorrhexis (CCC).

METHODS: Femtosecond capsulotomies (Alcon-LenSx Lasers Inc) and CCC were carried out in 20 eyes of 20 patients, respectively. Intraocular lens (IOL) decentration, circularity, vertical and horizontal diameters of capsulotomies, and capsule overlap were measured with Adobe Photoshop (Adobe Systems Inc) 1 week, 1 month, and 1 year after surgery. Between-group differences of parameters and predictors of IOL decentration were determined with repeated measures analysis of variance, chi-square test, and logistic regression analyses.

RESULTS: Vertical diameter of CCC was statistically significantly higher in the first week and month. Significantly higher values of capsule overlap over 1 year and circularity in the first week showed more regular femtosecond capsulotomies. Horizontal IOL decentration was statistically significantly higher in the CCC group over 1 year. A significant difference was noted between the two groups in dichotomized horizontal decentration values at 0.4 mm with chi-square test after 1 week and 1 year ($P=.035$ and $P=.016$, respectively). In univariable general estimating equation models, type of capsulorrhexis ($P<.01$) and capsule overlap ($P=.002$) were significant predictors of horizontal decentration. Vertical diameter showed significant correlation to the overlap in the CCC group (1 week: $r=-0.91$; 1 month: $r=-0.76$, $P<.01$; 1 year: $r=-0.62$, $P<.01$), whereas no significant correlation was noted in the femtosecond group ($P>.05$).

CONCLUSIONS: More precise capsulotomy sizing and centering can be achieved with femtosecond laser. Properly sized, shaped, and centered femtosecond laser capsulotomies resulted in better overlap parameters that help maintain proper positioning of the IOL. [*J Refract Surg.* 2011;27(8):558-563.]

doi:10.3928/1081597X-20110623-03

Creation of a precise anterior capsulorrhexis is one of the most important steps of cataract surgery. In recent years, the most commonly used technique during phacoemulsification is continuous curvilinear capsulorrhexis (CCC). Popularized by Gimbel and Neuhann,¹⁻³ CCC has several surgical and postoperative advantages but its completion takes special attention and surgical expertise. Obtaining a precise capsulorrhexis is essential to reach demanding refractive results because a properly sized and well-centered capsulorrhexis with a 360° overlapping capsular edge prevents optic decentration, tilt, myopic shift, posterior and anterior capsular opacification due to symmetric contractile forces of the capsular bag, and shrink wrap effect.⁴⁻¹⁰ However, an eccentric or irregularly shaped capsulorrhexis with a diameter extending beyond the optic edge may lose these advantages.

Until now, capsulorrhexis has been a manual procedure. With the advent of femtosecond lasers in ophthalmic surgery, a predictably sized and centered anterior capsulotomy became possible through a laser-tissue interaction known as photodisruption.¹¹ Femtosecond lasers were initially developed for LASIK flap creation during corneal refractive surgery. Recently introduced laser technology enables surgeons to achieve efficient lens fragmentation or liquefaction and precise and reproducible creation of capsulotomies and corneal incisions during refractive cataract surgery.¹¹⁻¹⁴

The purpose of this study was to measure and compare sizing and positioning parameters of the femtosecond laser capsulotomy with manual CCC during 1-year follow-up. We also studied the effects of these differences on IOL centration. To our knowledge, no such comparisons have been performed previously.

From Semmelweis University Budapest, Faculty of Medicine, Department of Ophthalmology, Hungary (Kránitz, Takacs, Miháltz, Kovács, Nagy); and Medical Faculty Mannheim, University of Heidelberg, Mannheim, Germany (Knorz).

Drs Knorz and Nagy are consultants to Alcon-LenSx Lasers Inc. The remaining authors have no financial interest in the materials presented herein.

Correspondence: Kinga Kránitz, MD, Semmelweis University Budapest, Dept of Ophthalmology, Mária u. 39, 1085 Budapest, Hungary. Tel: 36 20 825 8503; Fax: 36 1 317 9061; E-mail: kranitzkinga@gmail.com

Received: October 14, 2010; Accepted: June 3, 2011

Posted online: June 30, 2011

PATIENTS AND METHODS

Femtosecond capsulotomies were carried out in 20 eyes of 20 patients and manual CCC was performed in 20 eyes of 20 patients undergoing cataract surgery with IOL implantation. Each patient underwent a complete ophthalmologic evaluation. Patients with previous ocular surgery, trauma, active ocular disease, poorly dilated pupils, or known zonular weakness were excluded from the study.

The study was conducted in compliance with the Declaration of Helsinki, as well as with applicable country and local requirements regarding ethics committee/institutional review boards and other statutes or regulations regarding protection of the rights and welfare of human subjects participating in biomedical research. A written informed consent was obtained prior to surgery from every patient.

SURGERY

The surgical technique was standardized in each patient, except for the method of capsulorrhexis. All surgeries were performed by the same surgeon (Z.Z.N.).

After pupillary dilation (1 drop of tropicamide 0.5% every 15 minutes \times 3) and instillation of topical anesthetics (proparacaine HCl 0.5%), the femtosecond laser (Alcon-LenSx Lasers Inc, Aliso Viejo, California) was docked to the eye using a curved contact lens to appanate the cornea. The location of the crystalline lens surface was determined with an integrated optical coherence tomography imaging system. A 4.5-mm diameter capsulotomy procedure was performed by scanning a cylindrical pattern starting at least 100 μ m below the anterior capsule and ending at least 100 μ m above the capsule. Proprietary energy and spot separation parameters, which had been optimized in previous studies, were used for all laser procedures.

Following the laser capsulotomy procedure, a 2.8-mm clear corneal incision was created with the laser. The cut capsule was removed with capsule forceps under a standard ophthalmic operating microscope. A 4.5-mm capsulorrhexis was attempted in the CCC group and was performed with the aid of a cystotome and capsulorrhexis forceps. After hydrodissection, phacoemulsification of the nucleus and aspiration of the residual cortex were performed using the Accurus phacoemulsification machine (Alcon Laboratories Inc, Ft Worth, Texas). All IOLs were folded and implanted in the capsular bag with the aid of an injection cartridge through the corneal wound. All IOLs were three-piece or one-piece spherical lenses of hydrophobic acrylic material. The haptics of the IOL were situated in the same position (at 3 and 9 o'clock). The IOL power was calculated using the SRK/T formula. After IOL implantation, the viscoelastic material was removed from the anterior

chamber and capsular bag by irrigation/aspiration. No stromal hydration was needed. All incisions were left sutureless. No intra- or postoperative complications occurred. Within the first 10 days, all patients received a combination of antibiotic and steroid eye drops (dexamethasone and tobramycin).

MEASUREMENTS

To document capsulotomies, digital retroillumination photographs were taken 1 week, 1 month, and 1 year after surgery. Photographs were imported into Adobe Photoshop (Adobe Systems Inc, San Jose, California) for measuring IOL decentration and the following capsulotomy parameters: vertical and horizontal diameter, circularity, and the shortest and longest distance between the edge of capsulorrhexis and the IOL optic edge (distance min, distance max) along an elongated radius of capsulorrhexis. The diameter of the implanted IOL was used as a scale to eliminate the magnification effect of the cornea (Fig 1).

Intraocular lens decentration was evaluated according to Becker et al.¹⁵ The previously described method was altered by changing the reference point to the center of the pupil, because both the femtosecond capsulotomies and the manual procedures were aligned at the pupil center (Fig 2). To eliminate the effect of mydriatic drops on changing the position of the pupil center, the same amount and type of mydriatic drops were used to dilate patients' pupils before surgery and before taking the photographs.¹⁶

Adobe Photoshop gives a vector (determined by its length and angle to the horizontal plane) between the pupil center and center of the IOL. The length of the vector shows the total IOL decentration. Horizontal and vertical decentration were calculated using trigonometry analysis. To determine the magnitude of horizontal and vertical decentration without reference to nasal/temporal or up/down orientation, the absolute values of the above-mentioned parameters were counted.

Circularity is a parameter used for determining the regularity of capsulotomy shape according to the following formula: circularity = 4π (area/perimeter²). The quotient of the shortest and longest distance between the edge of the capsulorrhexis and the edge of the IOL optic was calculated to determine capsule-IOL overlap (overlap = distance min/distance max). Circularity and overlap values of 1.0 indicate a perfect circle and an absolute regularly overlapping anterior capsule on the optic of the implanted IOL, respectively.

Shifting of the visual axis from the pupil center was determined with a Lenstar biometer (Haag-Streit, Koeniz, Switzerland) in all eyes before and 1 year after cataract surgery.

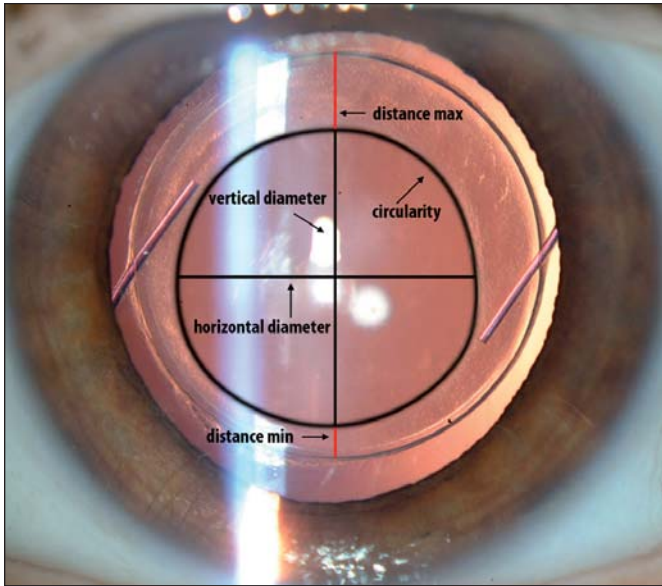


Figure 1. Parameters characteristic to the capsulorrhesis measured by Adobe Photoshop.




Figure 2. Decentration of the IOL from the pupil center.

STATISTICAL ANALYSES

Statistical analyses were performed with SPSS 16.0 (SPSS Inc, Chicago, Illinois). Departure from normal distribution assumption was tested by the Shapiro-Wilks W test. Due to normality of data, descriptive statistics show mean and standard deviation.

Differences between the two groups of capsulorrhesis parameters were analyzed using repeated measures analysis of variance (ANOVA) test with Newman-Keuls test.

To determine predictors of IOL decentration, logistic regression analyses were performed via univariable general estimating equation (GEE) models treating data from eyes of patients in statistical analysis as repeated measures. This technique took into account the correlated nature of data from patients who contributed two eyes to the repeated measurements. We dichotomized decentration parameters at the level of 0.4 mm, as previous results showed that <0.4-mm decentration provides the best optical performance whereas >0.4 mm can worsen the visual outcome of aspheric and wavefront-corrected IOLs.¹⁷

Chi-square test of homogeneity was applied to compare the distribution of dichotomized horizontal decentration values at 0.4 mm between the two study groups.

Correlations between vertical diameter and overlap parameters were analyzed with Spearman rank correlation.

The significance level was set at $P < .05$ in all statistical analyses.

RESULTS

No statistically significant differences were noted between the femtosecond (FS) and CCC groups in regards to age and gender distribution, refractive status, and axial length (Table 1).

Table 2 shows mean and standard deviation values of parameters characteristic to capsulotomies and IOL decentrations in the two study groups measured by Adobe Photoshop. Although capsulotomies were not perfectly round in the postoperative follow-up period in either the CCC or FS group, statistically significant differences were noted between the two groups at the given time point analyzed by repeated measures ANOVA. Vertical diameter was significantly higher 1 week and 1 month after surgery in the CCC group. Statistically significant differences were observed in the shortest and longest distance between the edge of the IOL optic and the edge of the capsulorrhesis 1 week and 1 month after surgery and in circularity 1 week after surgery. Significantly higher values of overlap and circularity showed more regular capsulotomies in the FS group. Horizontal decentration of the IOL was also significantly higher in the CCC group during the first year.

The type of capsulorrhesis was found to be a significant predictor of horizontal decentration in the univariable GEE model (odds ratio [OR]: 5.95, 95% confidence limit [CL]: 1.58-22.22, $P < .01$). When predictors of horizontal IOL decentration were explored, only capsulorrhesis overlap showed a significant effect ($P = .002$) among all capsulorrhesis parameters. Decentration was not influenced by type of implanted IOL according to a GEE model ($P > .05$). No statistically

significant differences in total decentration or decentration in horizontal or vertical direction were noted between one-piece and three-piece IOLs according to repeated measurements ANOVA test with Newman-Keuls test ($P > .05$).

The ratios of <0.4 mm and >0.4 mm horizontal decentration values were 4/16, 3/17, and 5/15 eyes in the CCC group 1 week, 1 month, and 1 year after surgery, respectively. Horizontal decentration did not exceed 0.4 mm in any eye in the FS group (0/20 at all time points) (Table 3). Chi-square test of homogeneity was applied to compare the distribution of dichotomized horizontal decentration values at 0.4 mm between the two study groups. A statistically significant difference was found between groups at 1 week and 1 year postoperatively ($P = .035$ and $.016$, respectively). No statistically significant difference was noted between the FS and CCC group 1 month after surgery ($P > .05$).

According to Figures 3-5, vertical diameter demonstrated a statistically significant correlation to the overlap in the CCC group at all three time points (1 week: $r = -0.91$, $P < .01$; 1 month: $r = -0.76$, $P < .01$; and 1 year: $r = -0.62$, $P < .01$), whereas no significant correlation was noted between the two parameters in the FS group ($P > .05$).

No statistically significant difference was observed in shifting of the visual axis from the pupil center in either absolute value or in horizontal or vertical direction 1 year postoperatively between groups ($P > .05$).

DISCUSSION

Cataract surgery techniques have undergone contin-

TABLE 1

Demographics of Patients Who Underwent Manual Continuous Curvilinear Capsulorrhexis or Femtosecond Laser Capsulotomy

Demographic	Manual CCC	Femtosecond	P Value
Age (y)	71.69±11.34 (52 to 84)	63.78±13.97 (28 to 86)	>.05
Gender (M:F)	6:14	5:15	>.05
MRSE (D)	-0.99±3.89 (-9.50 to 4.00)	-0.45±3.96 (-11.00 to 6.75)	>.05
Axial length (mm)	23.28±1.76 (20.32 to 27.76)	23.54±1.48 (20.32 to 26.55)	>.05

CCC = continuous curvilinear capsulorrhexis, MRSE = manifest refraction spherical equivalent
Note. Values presented as mean±standard deviation (range).

ued development since the introduction of phacoemulsification. However, with the advent of premium IOLs, an increasing need appeared for methods that ensure higher precision and predictability in cataract surgery. This is the first study to describe the better centration of IOLs 1 year after cataract surgery when capsulorrhexis was performed with a femtosecond laser.

A properly sized CCC provides several surgical advantages, and initial results with femtosecond laser showed higher precision of capsulorrhexis compared with manual techniques.¹¹

Corresponding to previous results where we com-

TABLE 2

Parameters of Capsulotomies and Intraocular Decentrations in Eyes That Underwent Continuous Curvilinear Capsulorrhexis or Femtosecond Laser Capsulotomy

Parameter	1 Week		1 Month		1 Year	
	CCC	Femtosecond	CCC	Femtosecond	CCC	Femtosecond
Vertical diameter (mm)	4.79±0.36	4.51±0.11*	4.62±0.34	4.47±0.21*	4.67±0.42	4.54±0.22
Horizontal diameter (mm)	4.60±0.47	4.60±0.18	4.64±0.31	4.57±0.24	4.69±0.37	4.61±0.31
Circularity	0.83±0.02	0.86±0.01*	0.84±0.03	0.85±0.02	0.85±0.02	0.84±0.03
Distance min (mm)	0.17±0.21	0.42±0.16*	0.26±0.24	0.47±0.19*	0.12±0.18	0.46±0.16*
Distance max (mm)	1.09±0.21	0.95±0.17*	1.12±0.17	0.96±0.23*	1.09±0.14	1.00±0.24
Overlap	0.17±0.19	0.47±0.24*	0.24±0.23	0.53±0.25*	0.13±0.19	0.54±0.31*
Horizontal decentration (mm)	0.28±0.16	0.12±0.11*	0.26±0.14	0.13±0.09*	0.30±0.16	0.15±0.12*
Vertical decentration (mm)	0.18±0.14	0.23±0.17	0.19±0.13	0.19±0.19	0.20±0.10	0.22±0.10

CCC = continuous curvilinear capsulorrhexis
* $P < .05$ between groups at the given time point using repeated measures analysis of variance.
Values presented as mean±standard deviation.

TABLE 3

Distribution of Horizontal Decentration Values >0.4 mm Between Eyes That Underwent Manual Continuous Curvilinear Capsulorrhexis and Femtosecond Laser Capsulotomy

Follow-up	FS Group	CCC Group	P Value
1 week	0/20	4/16	.035*
1 month	0/20	3/17	.072
1 year	0/20	5/15	.016*

FS = femtosecond laser, CCC = continuous curvilinear capsulorrhexis
 *P<.05 between groups using Chi-square test.

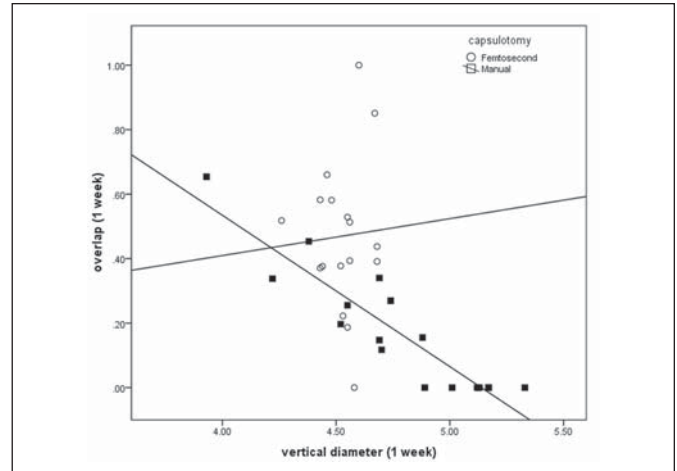


Figure 3. Correlation of vertical diameter to overlap 1 week after surgery. A statistically significant correlation was noted between the two parameters in the manual capsulorrhexis group ($r=-0.91$, $P=.01$), but no correlation was found between these parameters in the femtosecond capsulotomy group ($r=0.05$, $P>.05$).

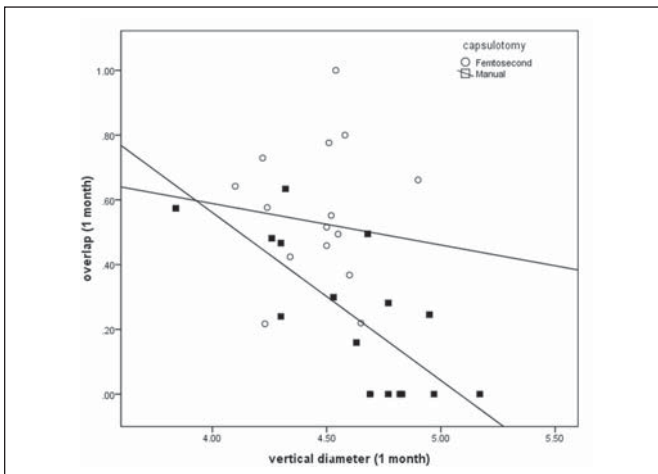


Figure 4. Correlation of vertical diameter to overlap 1 month after surgery. A statistically significant correlation was noted between the two parameters in the manual capsulorrhexis group ($r=-0.76$, $P<.01$), but no correlation was found between these parameters in the femtosecond capsulotomy group ($r=-0.11$, $P>.05$).

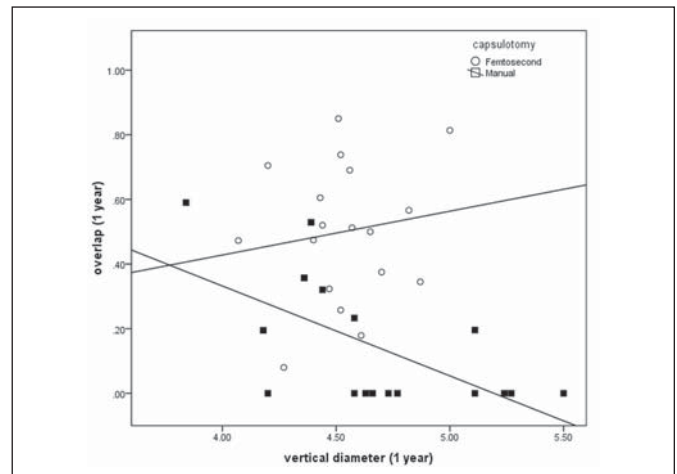


Figure 5. Correlation of vertical diameter to overlap 1 year after surgery. A statistically significant correlation was noted between the two parameters in the manual capsulorrhexis group ($r=-0.62$, $P=.01$), but no correlation was found in the femtosecond capsulotomy group ($r=0.14$, $P>.05$).

pared circularity of femtosecond capsulotomies and manually performed capsulorrhexis at 1 week, we observed more regular shape in the FS group.¹⁸ Difference in circularity between the two study groups can be explained by disproportion of vertical and horizontal diameter values in the CCC group. Properly sized, shaped, and centered femtosecond capsulotomies resulted in better overlap parameters during the first year. Worsening irregularity of manual capsulorrhexis through asymmetric contractile and vector forces aggravated the IOL centration over time. In our study, the length of vertical diameter correlated with the overlap of the anterior capsule in the manual capsulorrhexis

group. Figures 3-5 demonstrate how higher values of this parameter are able to lead to irregular anterior capsule overlap. A 360° overlapping capsular edge is thought to be an important factor for standardizing refractive results by keeping the IOL in the desired center position. The overlap sets not only the horizontal-vertical but also the anteroposterior positioning of the IOL.¹⁹

In our study, we examined decentration of implanted IOLs according to a previous report from Becker et al.¹⁵ Decentration >0.4 mm can deteriorate optical outcomes of accommodating and multifocal IOLs.¹⁷ Our results show statistically higher horizontal decentration in the CCC group 1 week and 1 year after IOL implantation

and a statistically significant difference in the distribution of dichotomized horizontal decentration values at 0.4 mm between the two study groups 1 week and 1 year after surgery. We found IOL decentration was six times more likely to occur when capsulorrhexis was performed manually. Moreover, it seems that “overlap” captures all characteristics of the capsulorrhexis shape. Among all capsulorrhexis parameters, only overlap showed significant effect on IOL horizontal decentration, representing the importance of precise sizing and centration of capsulotomy. During analysis of the centration results, we were able to statistically exclude the influence of implanted IOL type and larger capsular bag on IOL decentration because no statistically significant differences were found between the two study groups in preoperative refractive status or axial length. No differences in magnitude or direction of visual axis shifting from the pupil center were found between the two study groups that could influence the visual outcome of cataract surgery in relation to IOL decentration.

The limitation of our study is that we did not evaluate the anteroposterior position of the IOL. It would be interesting and important to examine whether the above described effect of regular femtosecond capsulotomies influences anteroposterior positioning and tilting of the IOL over time.

According to the results of our study, potential clinical advantages can be achieved during refractive cataract surgery through effective prevention of optic decentration with precisely controlled shape, size, and centration of capsulotomy with femtosecond laser. However, to present clinical relevance of more predictable postoperative IOL positioning, additional analyses are needed.

AUTHOR CONTRIBUTIONS

Study concept and design (K.K., K.M., Z.Z.N.); data collection (K.K., A.T., I.K.); analysis and interpretation of data (K.K., I.K., M.C.K., Z.Z.N.); drafting of the manuscript (K.K., I.K.); critical revision of the manuscript (A.T., K.M., I.K., M.C.K., Z.Z.N.); statistical expertise (K.K., K.M.); administrative, technical, or material support (K.K.); supervision (Z.Z.N.)

REFERENCES

1. Neuhann T. Theory and surgical technic of capsulorrhexis [German]. *Klin Monatsbl Augenheilkd*. 1987;190(6):542-545.
2. Gimbel HV, Neuhann T. Development, advantages, and methods of the continuous circular capsulorrhexis technique. *J Cataract Refract Surg*. 1990;16(1):31-37.
3. Gimbel HV, Neuhann T. Continuous curvilinear capsulorrhexis. *J Cataract Refract Surg*. 1991;17(1):110-111.
4. Ravalico G, Tognetto D, Palomba M, Busatto P, Baccara F. Capsulorrhexis size and posterior capsule opacification. *J Cataract Refract Surg*. 1996;22(1):98-103.
5. Aykan U, Bilge AH, Karadayi K. The effect of capsulorrhexis size on development of posterior capsule opacification: small (4.5 to 5.0mm) versus large (6.0 to 7.0mm). *Eur J Ophthalmol*. 2003;13(6):541-545.
6. Hollick EJ, Spalton DJ, Meacock WR. The effect of capsulorrhexis size on posterior capsular opacification: one-year results of a randomized prospective trial. *Am J Ophthalmol*. 1999;128(3):271-279.
7. Ram J, Pandey SK, Apple DJ, et al. Effect of in-the-bag intraocular lens fixation on the prevention of posterior capsule opacification. *J Cataract Refract Surg*. 2001;27(7):367-370.
8. Chang DF, Dewey S, Tipperman R, Wallace RB. Pearls for sizing the capsulorrhexis. *Cataract & Refractive Surgery Today Europe*. 2008;3(9):40-44.
9. Hayashi K, Hayashi H, Nakao F, Hayashi F. Anterior capsule contraction and intraocular lens decentration and tilt after hydrogel lens implantation. *Br J Ophthalmol*. 2001;85(11):1294-1297.
10. Hayashi H, Hayashi K, Nakao F, Hayashi F. Anterior capsule contraction and intraocular lens dislocation in eyes with pseudoexfoliation syndrome. *Br J Ophthalmol*. 1998;82(12):1429-1432.
11. Nagy Z, Takacs A, Filkorn T, Sarayba M. Initial clinical evaluation of an intraocular femtosecond laser in cataract surgery. *J Refract Surg*. 2009;25(12):1053-1060.
12. Ratkay-Traub I, Ferincz IE, Juhasz T, Kurtz RM, Krueger RR. First clinical results with the femtosecond neodymium-glass laser in refractive surgery. *J Refract Surg*. 2003;19(2):94-103.
13. Nordan LT, Slade SG, Baker RN, Suarez C, Juhasz T, Kurtz R. Femtosecond laser flap creation for laser in situ keratomileusis: six month follow-up of initial U.S. clinical series. *J Refract Surg*. 2003;19(1):8-14.
14. Tran DB, Sarayba MA, Bor Z, et al. Randomized prospective clinical study comparing induced aberrations with IntraLase and Hansatome flap creation in fellow eyes: potential impact on wavefront-guided laser in situ keratomileusis. *J Cataract Refract Surg*. 2005;31(1):97-105.
15. Becker KA, Auffarth GU, Völcker HE. Measurement method for the determination of rotation and decentration of intraocular lenses [German]. *Ophthalmologe*. 2004;101(6):600-603.
16. Yang Y, Thompson K, Burns SA. Pupil location under mesopic, photopic, and pharmacologically dilated conditions. *Invest Ophthalmol Vis Sci*. 2002;43(7):2508-2512.
17. Holladay JT, Piers PA, Koranyi G, van der Mooren M, Norrby NE. A new intraocular lens design to reduce spherical aberration of pseudophakic eyes. *J Refract Surg*. 2002;18(6):683-691.
18. Nagy ZZ, Kránitz K, Takacs AI, Miháltz K, Kovacs I, Knorz MC. Comparison of IOL decentration parameters after femtosecond and manual capsulotomies. *J Refract Surg*. 2011;27(8):564-569.
19. Cekiç O, Batman C. The relationship between capsulorrhexis size and anterior chamber depth relation. *Ophthalmic Surg Lasers*. 1999;30(3):185-190. Erratum in *Ophthalmic Surg Lasers*. 1999;30(9):714.